PHENYTOIN-INDUCED GINGIVAL OVERGROWTH –AN IMMUNOHISTOCHEMICAL STUDY OF TGF-β1 MEDIATED PATHOGENIC PATHWAYS

MONICA BANIȚĂ[1*], CĂTĂLINA PISOSCHI[1*], CAMELIA STĂNCIULESCU[1], VERONICA MERCUȚ[1], MONICA SCRIECIU[1], MIHAELA HÂNCU[2], MONICA CRĂIȚOIU[1]

[1]*University of Medicine and Pharmacy, 2 Petru Rareș Street, Craiova, Romania*
[2]*Ovidius University, 7 Ilarie Voronca Street, Constanța, Romania*
**corresponding authors: monban03@yahoo.com, c_pisoschi@yahoo.com*

Abstract

The frequency of phenytoin-induced gingival overgrowth (GO) has increased since its first report as a side effect years ago. Evidence indicate the alteration of collagen homeostasis as the main biochemical change but the precise mechanisms are still evaluated. We investigated the involvement of transforming growth factor - β1 (TGF-β1) mediated pathways in extracellular matrix (ECM) homeostasis in phenytoin-induced GO compared to the inflammatory conditions of periodontitis.

Immunohistochemistry disclosed an elevated response for TGF-β1 both in periodontitis and phenytoin-induced GO, in the second case being associated with an increased number of myofibroblasts and significant inhibition of collagen breakdown.

Rezumat

Incidența hipercreșterii gingivale apărută ca efect advers al tratamentului cu fenitoină a fost în continuă creștere de la menționarea sa ca reacție adversă cu ani în urmă. Numeroase studii indică alterarea homeostaziei colagenului drept principala modificare biochimică însă mecanismele exacte sunt încă discutate. Am evaluat implicarea căilor mediate de către factorul de creștere tumorală β1 (TGF-β1) în menținerea homeostaziei matricei extracelulare în hipercreșterea gingivală indusă de fenitoină comparativ cu modificările apărute în inflamația parodontală.

Studiul imunohistochimic a arătat o supraexprimare a TGF-β1 atât în inflamația parodontală cât și în hipercreșterea gingivală indusă de fenitoină, în cel de-al doilea caz fiind asociată cu o creștere a numărului de miofibroblaste, precum și cu inhibarea semnificativă a degradării colagenului.

Keywords: phenytoin, gingival overgrowth, transforming growth factor - β1 (TGF-β1), matrix metalloproteinases (MMP), tissue inhibiyot of metalloproteinases (TIMP), immunohistochemistry.

Introduction

Besides its involvement as a non-specific change induced by the inflammatory triggers, gingival overgrowth (GO) could arise most

commonly as a result of two major conditions:

- the long term ingestion of various medicines such as phenytoin, antihypertensive calcium channel blockers and immunosuppressants (such as cyclosporine);
- gingival fibromatosis, generally of an unknown etiology, that appears to have a strong genetic background.

The prevalence of GO among long term phenytoin and calcium channel blockers users is still increased [5,16].

Clinically and histologically, GO induced by medicines is virtually indistinguishable, having in common the enlargement of the gingival tissue due to the extracellular matrix (ECM) accumulation, although the pathogenic pathways seem to be strongly different [1, 11].

The drug induced alteration of connective tissue homeostasis is a topic which has been extensively researched [3,6,8-9,14-15]. The precise mechanisms involved in collagen accumulation in drug-induced GO are still investigated but the researches can be conventionally divided into those investigating collagen synthesis and those investigating collagen degradation.

One of the most important cytokine controlling collagen storage is the Transforming Growth Factor-β (TGF-β), mainly TGF-β1 isoform, that is known to selectively stimulate the production of ECM components and has been implicated in several fibrotic diseases associated with ECM accumulation [7,10].

In the same time, TGF-β1 is greatly involved in inflammation, being one of the cytokines expressed in pro-inflammatory cells [13].

The purpose of this immunohistochemical study was to evaluate the involvement of TGF-β1 mediated pathways (collagen synthesis in myofibroblasts and collagen breakdown through matrix metalloproteinases-MMP) on ECM homeostasis in phenytoin-induced GO compared to the inflammatory conditions of periodontitis.

Materials and methods

Gingival tissue samples

Gingival tissue samples were collected from phenytoin (Dilantin®) users for more than ten years (n=4) and individuals affected by periodontitis (n=11), as a control group. All gingival fragments were obtained with the informed consent of patients. Previously, the experimental protocol was approved by the Ethical Committee of the University of Medicine and Pharmacy, Craiova, Romania. None of the donors had received periodontal

treatment in the last years and all gingival biopsies were obtained prior to a periodontal therapy.

Histological analysis

Tissue samples were fixed in 4% buffered formalin and processed for paraffin embedding. Serial sections were colored with modified Masson trichrome staining and Gömöri's silver impregnation (Bio-Optica, Italy) in order to evaluate the collagen bundles thickness, distribution and the relative type I/type III collagen ratio in the *lamina propria*.

Immunohistochemical analysis

Sections were incubated in order to block the endogenous peroxidase and the unspecific binding. Then the slides were incubated over night, at 4°C, with the primary antibodies mentioned bellow:

Antibody	**Dilution**	**Source**
Mouse monoclonal anti-MMP-1	1:100	Santa Cruz Biotechnology
Mouse monoclonal anti-MMP-2	1:100	Santa Cruz Biotechnology
Mouse monoclonal anti-TIMP-1	1:100	Santa Cruz Biotechnology
Mouse monoclonal anti-human TIMP-2	1:100	Santa Cruz Biotechnology
Mouse monoclonal anti-human TGF-β1	1:200	Santa Cruz Biotechnology
Mouse monoclonal anti-human α-SMA	1:50	Dako

where: MMP – matrix metalloproteinases; TIMP – tissue inhibitor metalloproteinases; TGF-β1 - Transforming Growth Factor-β1; α-SMA – α-smooth muscle actim

The next day, sections were washed and processed for amplification of the immune signal using a polyclonal swine anti-mouse biotinylated IgG (Dako, USA) and the avidin-biotin complex (Vector Laboratories, USA). 3,3'-Diaminobenzidine tetrahydrochloride (Sigma-Aldrich Co., USA) and hydrogen peroxide were used for color development and Mayer hematoxylin (Bio-Optica, Italy) was used for nuclear counterstaining. Slides were observed and registered with a Nikon Eclipse microscope coupled to a digital camera. Images were finally processed using the Microsoft Office Picture Manager.

The evaluation of the immunohistochemical reactions was performed by two different observers according to the following: immuno-histochemical reactions (brown deposits in labeled structures) were graded as absent (negative or diffuse weak signal) or present (moderate or strong intensity of the signal), involving an evaluation of the mean signal in all microscopic fields from the whole slide.

For each tested antibody, a negative control was performed in which the primary antibody was replaced by phosphate buffer saline.

Results and discussion

The histological analysis of periodontitis (inflammatory) and phenytoin GO samples revealed both similar and different features: histological stains showed a general enlargement of the gingival mucosa, with a thick stratified squamous epithelium showing an alternation between keratinized with non-keratinized areas. The thickness of the epithelium is due to an important acanthosis observed in all the cases considered. The epithelium bended deeply into the underling connective tissue, forming the so called "rete pegs". These had also great variations of incidence and amplitude, being larger and deeper in the phenytoin-induced GO compared with periodontitis samples (Fig.1 a, b). The underlying connective tissue exhibited a variable number of fibroblasts, collagen bundles and blood vessels. In the *lamina propria* of phenytoin-GO samples we observed the constant presence of thick collagen bundles which ascended from the deep chorion into the loose connective tissue so the normal histological difference between them disappeared. A lot of elongated or pyramidal cells – fibroblasts were observed through the collagen bundles in phenytoin-induced GO samples while in periodontal inflammation cell populations were prevalent inflammatory (lymphocytes and macrophages).

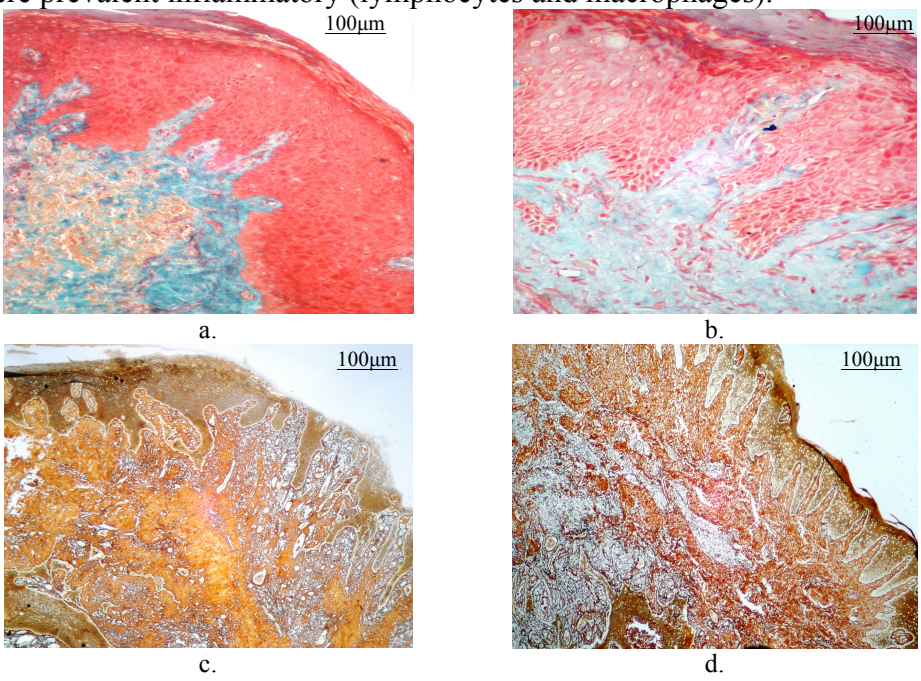

Figure 1

Morphological features of gingiva in periodontitis (a,c) and phenytoin-induced GO (b,d); a, b - Masson trichrome staining and c,d - Gömöri's silver impregnation.

Gömöri's silver impregnation showed an interesting difference between the composition of collagen bundles: in periodontitis, most of the collagen areas were colored in yellow proving the presence of type I collagen while in phenytoin samples the black color indicated an increased amount of type III collagen (Fig.1 c,d).

The expression of MMP-1 and MMP-2 was different for the periodontitis and phenytoin-induced GO samples: MMPs presented a diffuse positive reaction in few epithelial cells in the periodontitis samples (Fig.2 a, b) while both enzymes were absent in the phenytoin-induced GO samples (data not shown).

The immune reaction for tissue inhibitor of metalloproteinases-1 (TIMP-1) was positive in few epithelial cells from the periodontitis samples and negative in the phenytoin group (Fig.3 a, b).

For TIMP-2 immunoreaction the response was quite different.

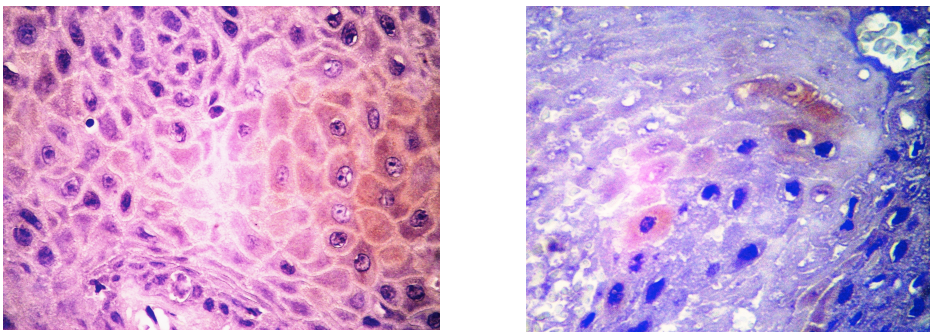

10µm a. 10µm b.

Figure 2

MMP-1 (a) and MMP-2 (b) immunohistochemical distribution in periodontitis GO.

Both types of GO showed highly positive for TIMP-2. In the periodontitis samples, we observed areas of TIMP-2 positive cells in the epithelium and a lot of TIMP-2 positive proinflammatory cells and few fibroblasts in the *lamina propria* (Fig.3c,d).

All the keratinocytes from the epithelial layers showed a constant high positivity for TIMP-2 in the phenytoin-induced GO samples (Fig.3e); in the *lamina propria*, the immune positive reaction was observed in many fibroblasts and also in endothelial and proinflammatory cells (Fig.3e,f).

For TGF-β1 distribution in the periodontitis samples, we noted a positive reaction in some keratinocytes from the basal epithelial layer and in the proinflammatory cells of some infiltrates in the *lamina propria* (Fig.4 a,b).

The positive reaction for TGF-β1 in the phenytoin-induced GO samples extended to many structures from the epithelium and lamina propria: keratinocytes, endothelial and proinflammatory cells (Fig.4 c,d).

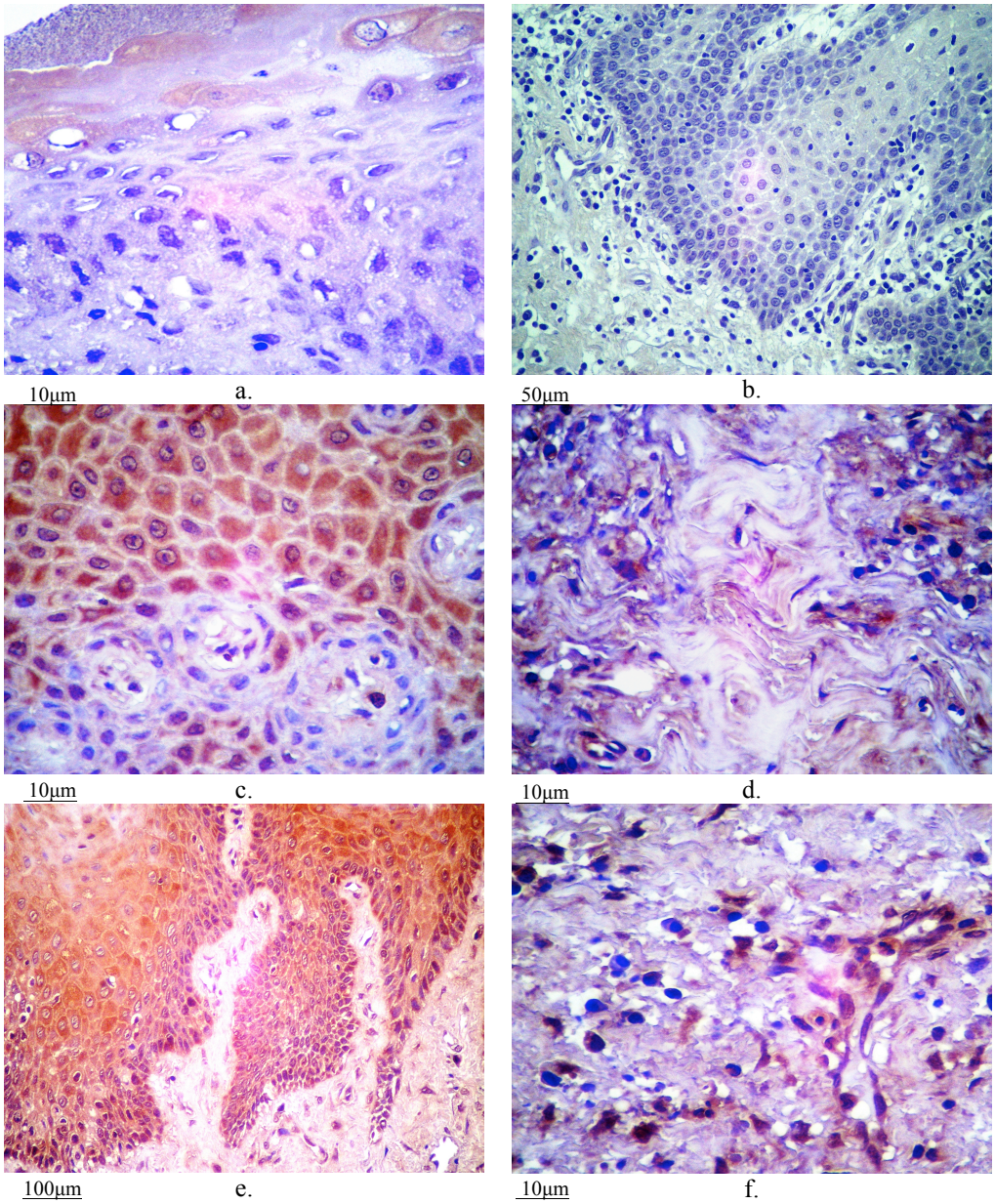

Figure 3

TIMP-1 (a, b) and TIMP-2 (c-f) immunohistochemical distribution in GO: a, c, d – samples of the periodontitis group; b,e,f – samples of the phenytoin-induced GO group.

In the periodontitis gingiva, the positivity for α-smooth muscle actin (α-SMA) noted only in the vessels walls (myocytes and pericytes) was considered as a positive internal control for the reaction (Fig.4e).

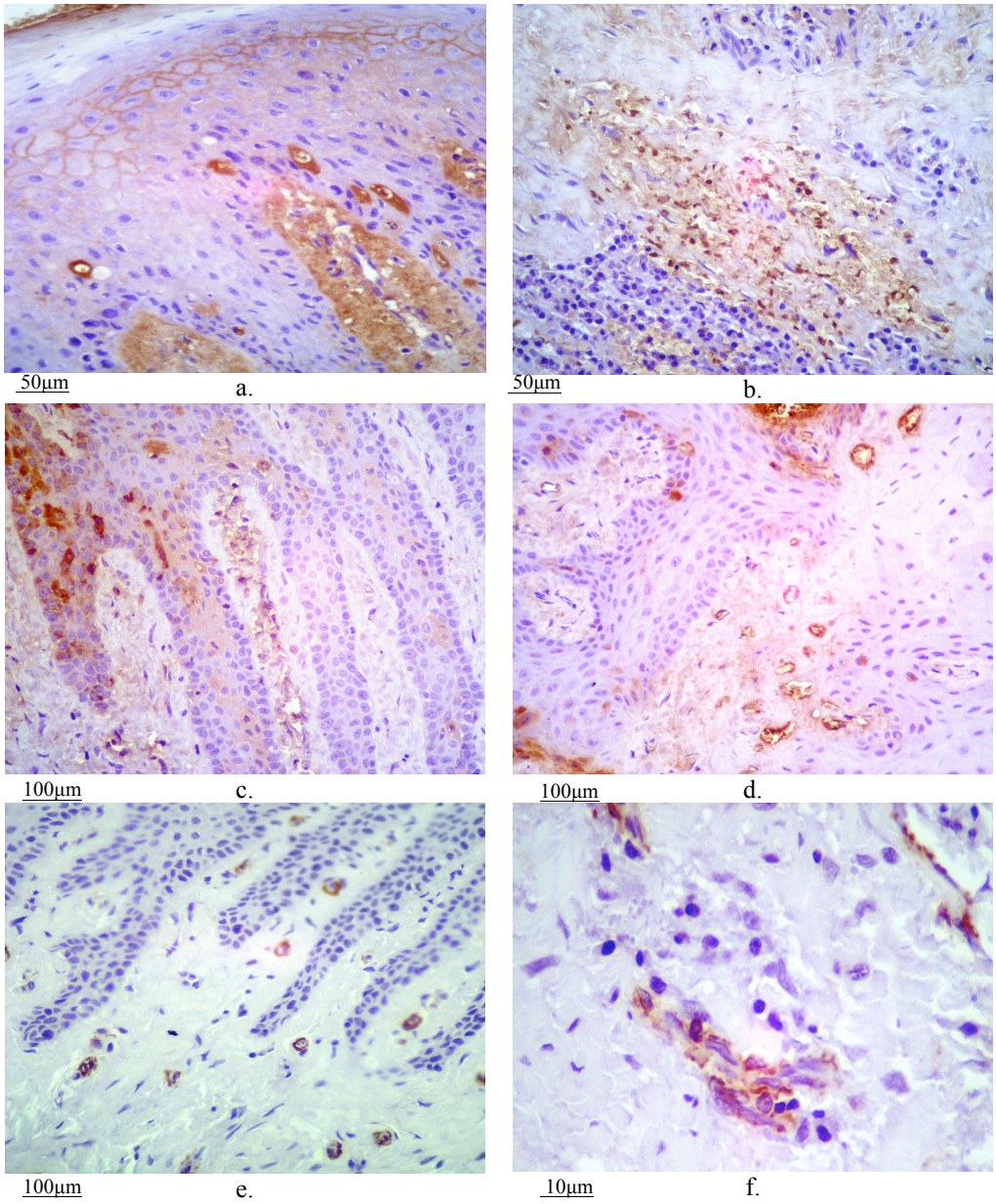

Figure 4

TGF-β1 (a-d) and α-SMA (e,f) immunohistochemical distribution in GO: a, b, e – samples of the periodontitis group; c, d, f – samples of the phenytoin-induced GO group.

The positive reaction for α-SMA in phenytoin-GO samples was observed not only in the vessel wall but also in some fibroblast-like mesenchymal cells, namely the myofibroblasts.

We noted that this type of cells had a peculiar distribution such as cellular foci between the collagen bundles (Fig.4f).

GO is a common condition due to the inflammation of the periodontium (gingivitis and periodontitis) but also to long term drug administration. Overgrown gingival tissue is generally characterized by an increase in connective tissue components (cells and ECM).

As we had presented in our images no peculiar histological aspects were observed in periodontitis and phenytoin administration, except a different amount of collagen fibers, greater in the phenytoin-GO samples.

The silver impregnation (a specific staining for fibril-forming collagen) has shown a different composition between the phenytoin-induced GO and inflammation, the former being associated with increased amounts of type III collagen, while the latter was associated with type I.

The collagen turnover is precisely balanced between collagen synthesis and degradation and, generally, fibrosis is caused by the loss of homeostasis between these two biological events.

It appears that the medication exerts its influence by modifying fibroblast phenotype and function, either directly or indirectly through altering the levels of cytokines or the MMP activity [1]. It has been hypothesized that phenytoin treated patients have fibroblasts with an abnormal susceptibility to the drug, characterized by elevated levels of collagen synthesis [5]. Because not all the patients taking phenytoin develop GO, such susceptibility could be related to a genetic predisposition, studies indicating that phenytoin and its major metabolite, 5-(parahydroxyphenyl)-5-phenyl-hydantoin (pHPPH), could react with a phenotipically distinct subpopulation of gingival fibroblasts [12].

TGF-β1 is a complex cytokine important not only in the inflammatory cascade but also in physiological (wound healing) and pathological fibrosis. It was demonstrated that in chronic periodontitis the increased inflammation is associated with high levels of TGF-β1 expression by the epithelial spindle cells [13, 18] fact that is in accordance with our observations.

The main effectors in the synthesis of collagen fibers promoted by TGF-β are the myofibroblasts, a subpopulation of fibroblast cells. Our results obtained for cellular α-SMA distribution showed the presence of α-SMA positive fibroblasts only in phenytoin-induced GO samples. We can suppose that this incidence is due to the extensive production of TGF-β1 in more gingival structures in case of phenytoin administration (not only in the chorionic structures but also in all epithelial layers).

Several studies emphasize that the disruption of collagen metabolism caused by phenytoin administration is due to the decreased collagen

degradation. MMPs are important mediators of connective tissue turnover, inducing tissue destruction in inflammatory pathology, including periodontitis, via interleukines synthesis by local activated macrophages and lymphocytes [2,4,9]. Even in oral diseases, the activity of MMP is regulated by two major classes of proteins:

- growth factors and cytokines, TGF-β1 being one of them;
- and TIMPs, natural tissue inhibitors of MMP [4,17].

The balance between the production of MMPs and TIMPs represent a critical point for maintaining the ECM homeostasis [4]. TIMP-1 is more effective than TIMP-2 in inhibiting MMP-1 and MMP-3 activities. Experimental evidences suggest that TIMP-2 is 10 times more effective than TIMP-1 in inhibiting the activity of MMP-2.

Our study indicated a decreased positivity for MMP-1, MMP-2 and TIMP-1 in periodontitis samples and an intense positivity for TIMP-2, while in phenytoin-induced GO samples was noted only an intense TIMP-2 positive reaction proving the wide distribution of this protein in all gingival structures. The absence of MMP-1, MMP-2 and TIMP-1 activities and the increased presence of TIMP-2 could be one of the factors responsible for the important accumulation of both type I and type III collagen, the other one being the intense fibrilogenetic activity of myofibroblasts induced by the TGF-β1 overexpression.

Conclusions

Histological features of phenytoin-induced GO showed an important accumulation of type I/type III collagen as a result of an imbalance between collagen synthesis and degradation promoted by the TGF-β1 overexpression.

In phenytoin-induced GO, TGF-β1 acts by two pathogenic pathways: the promotion of collagen synthesis by increasing the fibrilogenetic activity of myofibroblasts and the disruption of the balance between MMP-1 and MMP-2 and their specific tissue inhibitors.

Acknowledgments

This work was supported by CNCSIS-UEFISCSU, Ideas Project 1137/2009 "Morphological and biochemical study of the pathogenic pathways involved in collagen metabolism in gingival overgrowth".

References

1. Bartold M.P., Narayanan A.S., Molecular and cell biology of healthy and diseased periodontal tissues, *Periodontology 2000*, 2006, 40, 29-49
2. Beklen A., Ainola M., Hukkanen M., Gurcan C., Sorsa T., Konttinen Y.T., MMPs, Il-1

and TNF are Regulated by Il-17 in Periodontitis,*J. Dent.Res*.,2007,86(4),347-351
3. Castro L.A., Elias L.S.A., Oton-Leite A.F., de Spidula-Filho J.V., Leles C.R., Batista A.C., Long-term effects of nifedipine on human gingival epithelium a histopathological and immunohistochemical study, *J. Oral Science,* 2010,52(1),55-62
4. De Souza A.P., Line S.R.P., The Biology of Matrix Metalloproteinases, *Rev FOB*, 2002, 10(1),1-6
5. Dongari-Bagtzoglou A, Drug-Associated Gingival Enlargement, *J Periodontol*., 2004, 75, 1424-1431
6. Ellis J.S., Morgan C.L., Taylor J.J., Thomason J.M., Plasma TGF-β1 as a risk factor for gingival overgrowth, *J. Clin. Periodontol*., 2004,31,863-868
7. Gressner A. M., Weiskirchen R., Breitkopf K., Dooley S., Roles of TGF-beta in hepatic fibrosis, *Front. Biosci.,* 2002, (7),793-807
8. Kantarci A., Black S.A., Xydas C.E., Murawel P., Uchida Y., Yucecal-Tuncer B., Atilla G., Emingil G., Uzel M.I., Lee A., Firatli E., Sheff M., Hasturk H., Van Dyke T.E., Traskman P.C., Epithelial and Connective Tissue Cell CTGF/CCN Expression in Gingival Fibrosis, *J. Pathol*., 2006, 210(1), 59-66
9. Kataoka M, Kido J, Shinohara Y, Nagata T., Drug-Induced Gingival Overgrowth-a Review. *Biol. Pharm. Bull*., 2005,28(10),1817-1821
10. Kisseleva, T., Brenner, D.A., Mechanisms of fibrogenesis. *Exp. Biol. Med*., 2008,233, 109-122
11. Marshall R.I, Bartold P.M., Medication induced gingival overgrowth. *Oral Dis*., 1998, 4, 130-151
12. Seymour R.A., Thomason J M., Ellis J.S., The pathogenesis of drug-induced gingival overgrowth, *J. Clin. Periodontol*., 1996,23,165-175
13. Steinsvoll S., Halstensen TS., Schenck K., Extensive expression of TGFβ1 in chronically inflamed periodontal tissue, *J. Clin. Periodontol*., 1999,26,366-73
14. Trackman P.C., Diverse Biological Functions of Extracellular Collagen Processing Enzymes, *J. Cell Biochem.*, 2005,1,96(5), 927-937
15. Trackman P.C., Kantarci, A., Connective tissue metabolism and gingival overgrowth. *Crit. Rev. Oral. Biol. Med*., 2004,15(3),165-175
16. Vaughan S. Drug-induced gingival hyperplasia, *RGH Pharmacy E-Bulletin*, 2009, 35(10), 28
17. Verstappen J., Von de Hoff J.W., Tissue Inhibitors of Metalloproteinases (TIMPs): their Biological Functions and Involvement in Oral Disease, *J. Dent. Res.,* 2006,85(12),1074-1084
18. Wright H.J., Chapple I.L.C., Matthews J.V., TGF-β isoforms and TGF-β receptors in drug induced and hereditary gingival overgrowth. *J. Oral Pathol. Med.*, 2001, 30, 281-289

Manuscript received: March 11th 2010